



EVALUATION OF THE EFFECTIVENESS OF PSYCHODIAGNOSTIC METHODS IN VASCULAR DEMENTIA

Matmurodova .R.J

Xaqnazarova.M.S

*Tashkent State Medical University,
Tashkent, Uzbekistan*

Annotation. *The thesis presents various psychodiagnostic methods in patients with dementia. The research data showed that in patients with dementia, a short and easy examination of changes in both spheres using a single integral scale leads to an increase in the effectiveness of psychodiagnostics, rather than examining the cognitive and psychoemotional spheres of individual patients with MMSE and HADS scales.*


Keywords: *vascular dementia, MMSE, HADS, Integral scale, psychodiagnostics*

Vascular dementia most often develops after the age of 65, and there are some differences in prevalence between women and men. As shown by a number of large-scale meta-analyses, arterial hypertension, diabetes mellitus, and atherosclerosis increase the risk of vascular dementia by 2–3 times.

Vascular dementia is a complex disease characterized by not only cognitive but also psychoemotional disorders. The use of new psychodiagnostic methods and biomarkers is important in determining diagnosis and prognosis.

Vascular dementia is a progressive impairment of cognitive function caused by vascular factors, which develops as a result of stroke, small vessel pathology, lacunar infarcts, and microangiopathy. According to the World Health Organization, vascular dementia accounts for approximately 15–20% of dementia cases [1,3].

Currently, a significant increase in acute and chronic cerebrovascular pathology is observed all over the world, which allows us to consider vascular diseases of the brain as an urgent socio-medical problem, even called the "epidemic of the 20th century" [2,4,5]. In the Russian Federation, more than 450,000 cases of stroke are registered annually, the number of patients with chronic cerebral ischemia is more than 700 per 100,000 inhabitants [4,6,7]. Delayed diagnosis, inadequate prevention and treatment of dyscirculatory encephalopathy lead to an increase in the morbidity of patients and disruption of brain functions, which negatively affects work performance and social adaptation [8,10]. Among the various neurological symptoms that develop as a result of organic lesions, cognitive dysfunction is a significant problem, which significantly affects the quality of life of patients [9,10]. The issues of nosological differentiation of various variants of cognitive disorders, including those associated with cerebrovascular pathology, have been developed for many years, but the exact definition of vascular cognitive disorders is still not fully defined, there are no generally accepted classification and diagnostic criteria. The data on the significance of cerebrovascular pathology in cognitive impairment are contradictory. According to



epidemiological data, in many countries of the world, vascular dementia is second only to Alzheimer's disease in prevalence and accounts for 20-25% of all cases [9,11]. The incidence of vascular dementia ranges from 1.5 to 3.3 per 1000 elderly people [12,13]. In the field of practical medicine, there is no consensus on the role of various brain lesions in the development of vascular cognitive disorders. With the advent of functional neuroimaging methods, such as OFECT and PET, it has become possible not only to detect early brain function disorders, but also to study the order of formation of various cognitive disorders [14]. At the same time, the place and role of these modern methods in everyday clinical practice have not been clearly defined. To date, no significant studies have been conducted in Uzbekistan to study the possibilities of using functional neuroimaging methods in the differential diagnosis of vascular cognitive disorders. Pathomorphological studies in vascular dementia are mainly limited to describing the structural damage to brain structures and the vascular supply. However, it has not yet been determined which changes in the brain are vascular and their contribution to the development of cognitive disorders [15]. There are no studies that compare in detail the pathomorphological changes in the combined vascular-degenerative process using simpler light and electron microscopy techniques. In recent years, certain progress has been made in the field of prevention and treatment of cognitive disorders, which is associated with the emergence of modern drugs capable of influencing the formational pathogenesis of cognitive deficits [16]. However, today there are no generally accepted schemes for the treatment of vascular cognitive disorders, therefore, it is very urgent to develop recommendations that differentiate the risks of drugs in different clinical and pathogenetic variants. Thus, a detailed study of the etiopathogenetic and clinical patterns of various cognitive disorders in vascular pathology is an important and urgent scientific problem of modern neurology.

Epidemiological studies show that vascular dementia most often develops after the age of 65, and there are certain differences in prevalence between women and men. As shown by a number of large-scale meta-analyses, arterial hypertension, diabetes mellitus, and atherosclerosis increase the risk of vascular dementia by 2–3 times.

The main clinical feature of vascular dementia is a decline in cognitive functions (memory, attention, thinking, speech) and, along with them, the manifestation of psychoemotional and interpersonal disorders. This condition seriously affects the patient's social adaptation, daily life activities, and relationships with family members.

This research paper highlights new modern methods for identifying cognitive and psychoemotional disorders in patients diagnosed with vascular dementia and their advantages.

The aim of the study: Evaluation of the effectiveness of psychodiagnostic methods in vascular dementia

Research materials and methods.

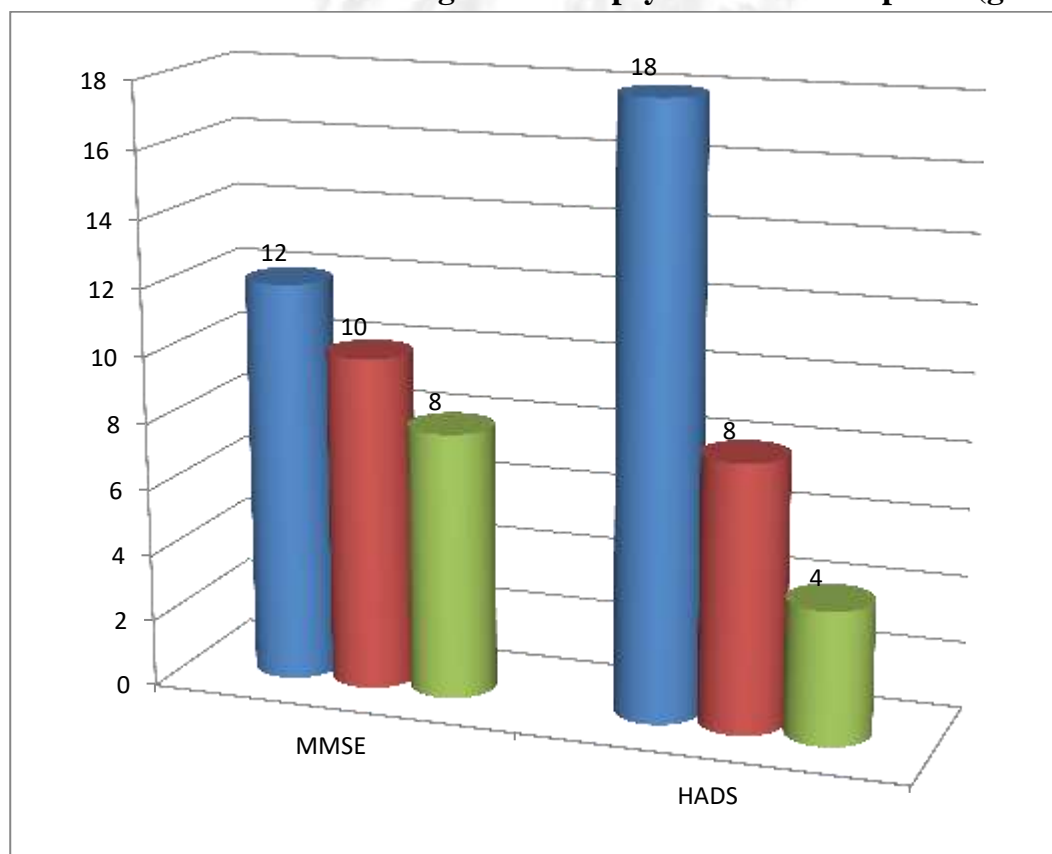
Vascular dementia 62 patients aged 55-63 years with schizophrenia were examined. Their average age was 58.2. In order to determine the effectiveness of psychodiagnostics in patients, they were conditionally divided into two groups:

Group 1: n=30 MMSE was used to determine changes in cognitive functions in vascular dementia, and HADS was used to determine changes in the emotional sphere.

Group 2: n=30 To determine changes in the cognitive and psychoemotional spheres in vascular dementia Vascular dementia integrated screening scale was applied.

In group 1, cognitive impairment was assessed using the MMSE scale, and three levels of dementia were found in the patients. In particular, mild dementia was detected in 12 patients (40.1%), moderate dementia in 10 patients (33.3%), and severe dementia in 8 patients (26.6%). In this group, psychoemotional disorders were assessed using the HADS scale, and three levels of anxiety and depressive disorders were detected: mild anxiety in 18 patients (60.1%), moderate anxiety in 8 patients (26.6%), and severe anxiety in 4 patients (13.3%), mild depression in 16 patients (60.1%), moderate depression in 10 patients (26.6%), and severe depression in 4 patients (13.3%) (Figure 1).

Results of examination of the cognitive and psychoemotional sphere (group 1)



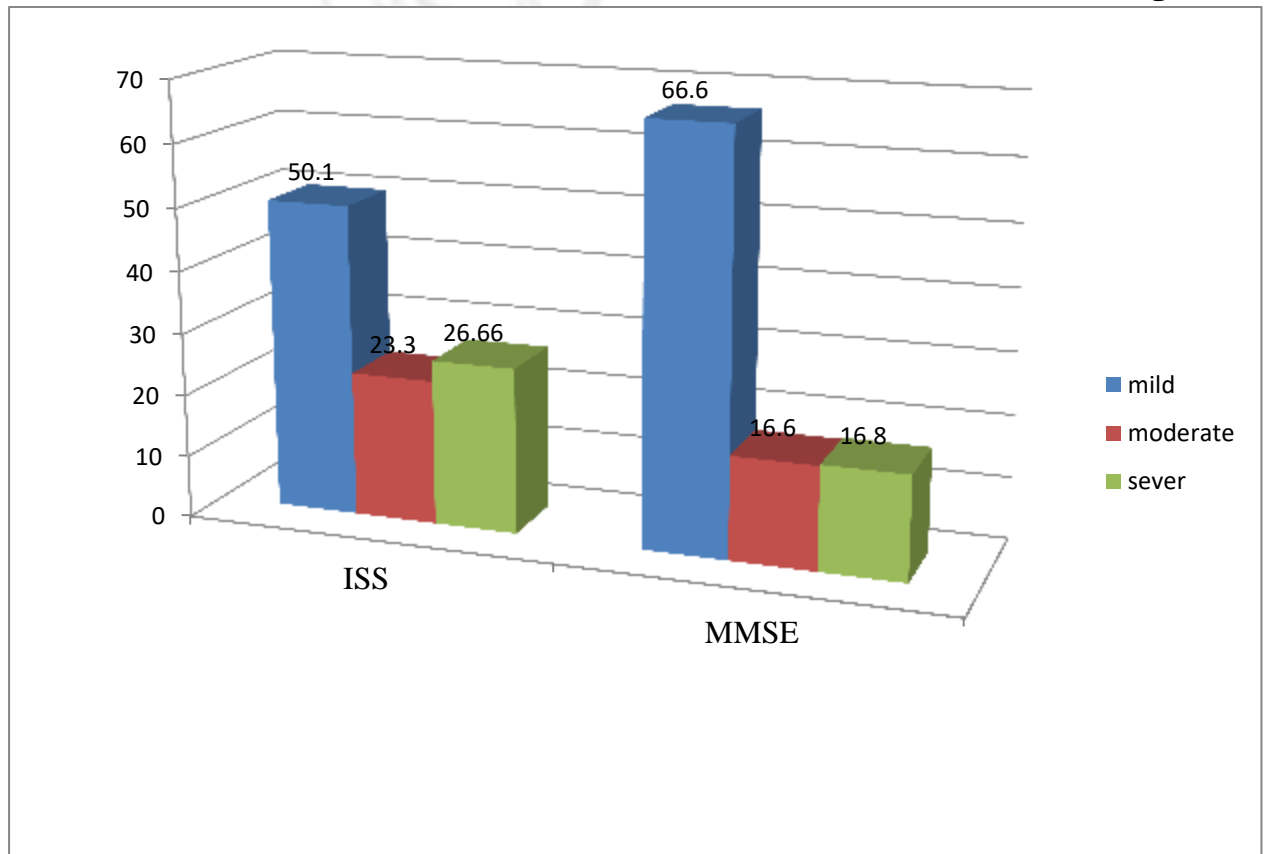
($p < 0.05$)

The tests for the state of cognitive and emotional block in vascular dementia in group 2 patients, as determined by the integrated screening scale, are as follows: Mild in 15 patients (50.1%) disorders, 7 patients (23.3%) had moderate to severe disorders, 8 patients

(26.6%) had severe disorders was found. When changes in the cognitive and psychoemotional spheres were examined and analyzed separately in this group, According to the MMSE scale We also present the results: 16 patients (66.6%) had mild cognitive impairment, 7 patients (16.6%) had moderate to severe cognitive impairment, 7 patients (16.8%) had severe cognitive impairment was determined (Figure 2).

Results of examination of the cognitive and psychoemotional sphere (group 2)

Figure 2




($r < 0.05$)

Thus, the results of our study indicate that it is more effective to assess cognitive and psychoemotional disorders in patients with vascular dementia using the MMSE scale and the HADS scale separately. Vascular dementia integrated screening scale It was found to be effective for quick and easy determination in a short time using a single scale.

References:

1. Albert MS, Dekosky ST, Dickson D, Dubois B, Feldman HH, Fox NC, Hamst A, Holtzman DM, Jagust WJ, Petersen RC (2011). The diagnosis of mild cognitive impairment due to alzheimer's disease. *Alzheimer's & Dementia*, 7(3): 270–279.
2. Fazekas f., kleinert r., offenbacher h., schmidt r., kleinert g., payer f., radner h., lechner h. (1993). Pathologic correlates of incidental mri white matter signal hyperintensities. *Neurology*, 43(9): 1683–1689.

- 
3. Gauthier s., rockwood k., camicioli r., black se, bocti c., darvesh s., hogan db, kertesza., poirier j., legault v., massoud f. (2006). Recommendations for the diagnosis and management of vascular cognitive impairment. *Canadian medical association journal*, 176(9): 1131–1138.
4. Gorelick pb, scuteri a., black se, decarli c., greenberg sm, iadecola c., launer lj, laurent s., lopez ol, nyenhuis d. (2011). Vascular contributions to cognitive impairment and dementia: a statement for healthcare professionals. *Stroke*, 42(9): 2672–2713.
5. Hamilton m. (1959). The assessment of anxiety states by rating. *British journal of medical psychology*, 32(1): 50–55.
6. Henry jd, crawford jr (2004). Verbal fluency deficits in dementia of the alzheimer's type: a meta-analysis. *Neuropsychology*, 18(1): 138–145.
7. Marin rs (1991). Apathy: a neuropsychiatric syndrome. *Journal of neuropsychiatry and clinical neurosciences*, 3(3): 243–254.
8. Marin rs, biedrzycki rc, firinciogullari s. (1991). Reliability and validity of the apathy evaluation scale. *Psychiatry Research*, 38(2): 143–162.
9. Miyake A., Friedman NP, Emerson MJ, Witzki AH, Howerter A., Wager TD (2000). The unity and diversity of executive functions and their contributions to complex "frontal lobe" tasks. *Cognitive psychology*, 41(1): 49–100.
10. Nasreddine zs, phillips na, bédirian v., charbonneau s., whitehead v., collin i., cummings jl, chertkow h. (2005). The montreal cognitive assessment (moca): a brief screening tool for mild cognitive impairment. *Journal of the American Geriatrics Society*, 53(4): 695–699.
11. O'brien jt, erkinjuntti t., reisberg b., roman g., sawada t., pantoni l., bowler jv, ballard c., decarli c., gorelick pb (2003). Vascular cognitive impairment. *The lancet neurology*, 2(2): 89–98.
12. Pantoni l. (2010). Cerebral small vessel disease: from pathogenesis and clinical characteristics to therapeutic challenges. *Lancet neurology*, 9(7): 689–701.
13. Petersen rc (2014). Mild cognitive impairment. *Continuum (minneapolis)*, 20(2): 404–418.
14. Prins n.d., scheltens p. (2015). White matter hyperintensities, cognitive impairment and dementia: an update. *Nature reviews neurology*, 11(3): 157–165.
15. Reijmer yd, van dijk ej, barkhof f., scheltens p., biessels gj (2013). Progression of cerebral small vessel disease and decline in information processing speed, executive function and memory. *Brain*, 136(9): 3699–3708.
16. Roman gc, sachdev p., royall dr, bullock ra, orgogozo jm, lopez-pousa s., arizaga r., acosta d., vellas b. (2004). Vascular cognitive disorder: a new diagnostic category. *Journal of neurological sciences*, 226: 81–87.